


Provided for non-commercial research and education use.
Not for reproduction, distribution or commercial use.



This article appeared in a journal published by Elsevier. The attached copy is furnished to the author for internal non-commercial research and education use, including for instruction at the authors institution and sharing with colleagues.

Other uses, including reproduction and distribution, or selling or licensing copies, or posting to personal, institutional or third party websites are prohibited.

In most cases authors are permitted to post their version of the article (e.g. in Word or Tex form) to their personal website or institutional repository. Authors requiring further information regarding Elsevier's archiving and manuscript policies are encouraged to visit:

<http://www.elsevier.com/copyright>

Available online at www.sciencedirect.com

SciVerse ScienceDirect

journal homepage: www.elsevier.com/locate/psyneuen

Effects of androgenization on the white matter microstructure of female-to-male transsexuals. A diffusion tensor imaging study

Giuseppina Rametti^{d,f}, Beatriz Carrillo^a, Esther Gómez-Gil^c,
Carme Junque^{b,f}, Leire Zubiaurre-Elorza^{b,f}, Santiago Segovia^a,
Ángel Gomez^e, Kazmer Karadi^g, Antonio Guillamon^{a,*}

^aDepartamento de Psicobiología, UNED, Madrid, Spain

^bDepartamento de Psiquiatría y Psicobiología Clínica, Universidad de Barcelona, Barcelona, Spain

^cUnidad de Identidad de Género, Hospital Clinic, Universidad de Barcelona, Barcelona, Spain

^dClinical Institute of Neuroscience, Hospital Clinic i Provincial, Barcelona, Spain

^eDepartamento de Psicología Social y de las Organizaciones, UNED, Madrid, Spain

^fInstitute of Biomedical Research August Pi i Sunyer (IDIBAPS), Barcelona, Spain

^gInstitute of Behavioral Science, Medical University of Pecs, Pecs, Hungary

Received 14 November 2011; received in revised form 20 December 2011; accepted 20 December 2011

KEYWORDS

Diffusion tensor imaging;
Transsexualism;
Sex differences;
Superior longitudinal
fasciculus;
Corticospinal tract;
Female to male
transsexuals;
Testosterone

Summary Diffusion tensor imaging (DTI) can sensitively detect white matter sex differences and the effects of pharmacological treatments. Before cross-sex hormone treatment, the white matter microstructure of several brain bundles in female-to-male transsexuals (FtMs) differs from those in females but not from that in males. The purpose of this study was to investigate whether cross-sex hormone treatment (androgenization) affects the brain white matter microstructure. Using a Siemens 3 T Trio Tim Magnetom, DTI was performed twice, before and during cross-sex hormonal treatment with testosterone in 15 FtMs scanned. Fractional anisotropy (FA) was analyzed on white matter of the whole brain, and the latter was spatially analyzed using Tract-Based Spatial Statistics. Before each scan the subjects were assessed for serum testosterone, sex hormone binding globulin level (SHBG), and their free testosterone index. After at least seven months of cross-gender hormonal treatment, FA values increased in the right superior longitudinal fasciculus (SLF) and the right corticospinal tract (CST) in FtMs compared to their pre-treatment values. Hierarchical regression analyses showed that the increments in the FA values in the SLF and CST are predicted by the free testosterone index before hormonal treatment. All these observations suggest that testosterone treatment changes white matter microstructure in FtMs.

© 2011 Elsevier Ltd. All rights reserved.

* Corresponding author. Tel.: +34 91 398 62 72; fax: +34 91 398 62 87.
E-mail address: aguillamon@psi.uned.es (A. Guillamon).

1. Introduction

Transsexuals are characterized by a persistent cross-gender identification and discomfort with their assigned gender (American Psychiatric Association, 2000); they show cross-dressing and a search for hormonal and surgical sex reassignment to the desired anatomical sex. It seems that biological variables may contribute to transsexualism (Cohen-Kettenis and Gooren, 1999; Savic et al., 2010). The approach to the brain of transsexuals has been made from the angle of brain sex differences. This strategy has been followed in neuroanatomical post mortem studies (Zhou et al., 1995; Kruijver et al., 2000; Garcia-Falgueras and Swaab, 2008) as well as structural (Hulshoff Pol et al., 2006; Luders et al., 2009; Rametti et al., 2011a,b; Savic and Arver, 2011) and functional (Berglund et al., 2008; Sommer et al., 2008; Gizewski et al., 2009; Carrillo et al., 2010; Schöning et al., 2010) MRI studies.

In relation to the white matter, there are only a handful of MRI studies in transsexuals. Emory et al. (1991) found no differences for the whole corpus callosum (CC) between male to female transsexuals (MtFs) and FtMs and controls. However, Yokota et al. (2005) showed that the pattern of CC shape in transsexuals is closer to that of individuals with the same gender identity than to individuals of the same biological sex.

DTI is an excellent technique for detecting subtle changes in the white matter of patients with psychiatric disorders (Nucifora et al., 2007) and has been used to investigate sex differences in normal adults (Westerhausen et al., 2003; Huster et al., 2009) as well as in developmental studies (Schmithorst et al., 2008). White matter microstructure has been studied in FtMs and MtFs before cross-sex hormonal treatment (Rametti et al., 2011a,b). Recently, we used DTI to investigate whether the white matter patterns of FtMs who had not begun cross-sex hormone treatment were more similar to those of their biological sex or to those of their gender identity (Rametti et al., 2011a). We found sex differences in the white matter microstructure of some brain bundles involved in higher cognitive functions. In these bundles, compared to control females, FtMs showed higher fractional anisotropy (FA) values in the anterior and posterior parts of the right superior longitudinal fasciculus (SLF) and the forceps minor (FM). However, in the corticospinal tract (CST), FA values in FtMs are significantly lower than in males and significantly higher than in females. Accordingly, we suggested that the white matter microstructure pattern in FtMs was closer to the pattern of subjects who share their gender identity (males) than to those who share their biological sex (females).

Genetically, FtMs are females shifting to live as men. In consequence, their hormonal treatment is directed toward masculinizing their body, so they receive regular or depot doses of testosterone. It is well known that sex hormones act on gray and white matter in the mammalian brain. In gray matter, androgen (AR) (Puy et al., 1995; Abdelgadir et al., 1999; Finley and Kritzer, 1999; Beyenburg et al., 2000; Bezdickova et al., 2007) and estrogen (ER) receptors (Österlund et al., 2000a,b) have been observed in the human and other primates cortices. Moreover, androgen (Fernández-Guasti et al., 2000), as well as alpha (Kruijver et al., 2002) and β -estrogen (Kruijver et al., 2003) receptors have

been detected in preoptic–hypothalamic areas. In addition, androgen receptors have also been identified in axons, dendrites and glial cells in the rat cortex and amygdala (DonCarlos et al., 2003, 2006; Sarkey et al., 2008) as well as in astrocytes and oligodendrocytes in the primate prefrontal cortex (Finley and Kritzer, 1999). Moreover, androgen treatment has been reported to raise total brain and hypothalamus volumes toward male levels in FtMs (Hulshoff Pol et al., 2006).

Large studies of the adolescent brain suggest that testosterone, acting through the AR, increases the volume of the white matter (Perrin et al., 2008). The same group has shown that in male adolescents a functional polymorphism of AR moderates the effect of testosterone on the relative white and gray matter volumes (Paus et al., 2010). However, the repetition of CAG repeat numbers in exon 1 of AR did not show significant differences in allelic or genotypic distribution between FtMs and control females (Ujike et al., 2009).

Taking into account the fact that gray and white matter have ARs (Puy et al., 1995; Abdelgadir et al., 1999; Finley and Kritzer, 1999; Beyenburg et al., 2000; DonCarlos et al., 2003, 2006; Bezdickova et al., 2007; Sarkey et al., 2008), and that testosterone increases the volume of the white matter in male adolescents (Perrin et al., 2008) and of total brain and hypothalamus volumes in FtMs (Hulshoff Pol et al., 2006), the aim of the present study was to investigate the possible effect of androgenization on white matter microstructure in FtMs. To answer this question we performed a follow-up DTI study in FtMs comparing the FA values from the same individuals before and during the androgenization treatment.

2. Methods

2.1. Subjects

The study sample was comprised of 15 FtMs recruited at the Gender Identity Unit (GIU) at the Hospital Clinic of Barcelona (see Gómez-Gil et al., 2009). The subjects in the present study are fifteen not-yet androgen treated individuals from the eighteen reported in a previous cross-sectional study (Rametti et al., 2011a). Diagnostic assessment of transsexualism followed the revised fourth edition of the Diagnostic and Statistical Manual of Mental Disorders (DSM-IV-TR; American Psychiatric Association, 2000) and the tenth revision of the International Classification of Diseases (ICD-10; World Health Organization, 1993) and was made after several semi-structured interviews with two mental health professionals (psychiatrist and psychologist) (Gómez-Gil et al., 2009). Psychological criteria for the diagnosis and treatment followed the guidelines provided by the Harry Benjamin International Gender Dysphoria Association (Meyer et al., 2002).

All FtMs selected had early-onset gender nonconformity (before puberty), were erotically attracted to females, and were interested in sex reassignment (Gómez-Gil et al., 2009). Sexual orientation in patients was established by asking what partner (a man, a woman, both or neither) the patient would prefer or feel attraction to if they were completely free to choose and the body did not interfere. For initial study enrollment, subjects needed to report no history of hormonal

treatment and declare their intention of undergoing androgen replacement therapy. They were scanned a few days before the start of hormonal treatment and again after at least 7 months of hormonal treatment. Exclusion criteria for all subjects were a history of head trauma, a diagnosed neurological disorder or major medical condition, and/or drug or alcohol abuse in the year prior to the study. The work was conducted in accordance with the Declaration of Helsinki. The Ethical Committee of the Hospital Clinic of Barcelona approved the protocol. All subjects gave written informed consent.

2.2. Hormone treatment and measurements

According to the GIU hormonal protocol, FtMs received either an intramuscular depot injection of testosterone every 10–14 weeks or daily transdermal testosterone gel. The hormone administration route and schedule was defined by patients' personal preferences.

The hormonal levels of transsexuals were controlled by routine hospital testing and hormonal data. The analyses closest in time to the scanning were assessed for the purpose of this study. Table 1 shows hormonal data before and during cross-sex hormonal treatment. Competitive chemoluminescent immunoassays were run for serum testosterone (Cobas, Roche; sensitivity 10 ng/dL); a sandwich type chemoluminescent immunoassay was employed for sex hormone binding globulin (SHBG) (Cobas, Roche; sensitivity 0.4 nm/L). The free testosterone index, which is a good approximation to bioavailable testosterone in women, was calculated as a percentage, dividing testosterone (nmol/L) by SHBG (nmol/L) \times 100 (Vermeulen et al., 1999; Miller et al., 2004).

2.3. Imaging protocol

All MR images were acquired with a 3-T magnet (SIEMENS Trio Tim Magnet, Erlangen, Germany) at the Hospital Clinic of Barcelona. Diffusion tensor imaging was acquired twice, before and after hormonal treatment, in all subjects using a full tensor diffusion MRI sequence based on a single shot spin echo planar imaging (EPI) in the axial plane (TR/TE = 9300/94, flip angle 90, at a slice thickness of 2.0 mm, providing 1.97 mm in-plane resolution). The images were

acquired in 64 noncolinear directions ($b = 1000 \text{ mm}^2/\text{s}$). The approximate scanning time for the DTI acquisition was 10 min.

Following the DTI acquisition, a high-resolution T1-weighted magnetization prepared a rapid gradient-echo (MP-RAGE) 3D MRI sequence in the sagittal plane (TE/TR = 2.98/2300 ms, TI = 900, field of view (FOV) = $25 \times 25 \text{ cm}$, matrix size 256×256 , and voxel size $1 \text{ mm} \times 1 \text{ mm} \times 1 \text{ mm}$) to permit detailed localization of diffusion maps.

2.4. Tract-Based Spatial Statistics (TBSS)

DTI data analysis was performed following the standard procedure of voxelwise analysis using TBSS (Smith et al., 2004), which is provided in the FSL software package (<http://www.fmrib.ox.ac.uk/fsl/>). First, we used SIENAX (Smith, 2002) to estimate gray matter, white matter, cerebrospinal fluid and intracranial volume, normalized for subject head size.

After the eddy current correction (linear alignment to the reference scan using FLIRT), we extracted the brain matter on the B0 image, using the Brain Extraction Tool (BET) supplied with the FSL software; a fractional intensity threshold of 0.2 was used for this step. Using the brain extracted B0 image, we then extracted the brain for the FA images, and resulting FA volumes were used in the TBSS analysis. Non-linear transformations were applied using the FSL registration tool, FNIRT, to obtain FA images aligned to a standard space (Andersson et al., 2007a,b).

Direct registration of individual FA volumes to the FMRIB58 template was applied; the mean FA-image was created following registration and thinned to represent the mean FA skeleton, which corresponds to the centers of all tracts common to the group. Individual FA volumes were then projected onto this common skeleton. An FA threshold of 0.2 was used to differentiate between gray and white matter.

Following these steps, data were fed into a voxelwise statistical analysis of individual skeleton images of the two groups. The analyses were performed using a non-parametric permutation test (randomized) and a standard GLM design for the whole brain. We applied a paired t -test with a p value of $<.05$ FWE, corrected for multiple comparisons. We used the Threshold-Free Cluster Enhancement (TFCE) method to

Table 1 Sample characteristics and hormonal levels before and during testosterone treatment of a group of female-to-male transsexuals.

	FtMs ^a pre-androgenized	FtMs androgenized	t	p Values
Age (years)	24.93 \pm 7.37	26 \pm 7.73		
Education ^b	10.00			
Months of treatment		9.80 \pm 2.04		
Hormonal levels ^c				
Serum testosterone (ng/dL)	51.84 \pm 20.12	749.17 \pm 257.96	10.34	<.001
Sex hormone binding globulin (nmol/L)	55.77 \pm 27.38	29.07 \pm 15.48	5.94	<.001
Free testosterone index (%)	4.21 \pm 3.15	111.95 \pm 63.10	6.82	<.001

^a FtM: female to male transsexuals. Results are expressed as mean \pm standard deviation.

^b Educational level expressed as the median of the number of years of education.

^c Normal serum testosterone levels: adult males (275–280 ng/dL) and females (10–80 ng/dL). Normal levels of sex hormone binding globulin: adult males (10–60 nmol/L) and females (35–135 nmol/L). Normal free testosterone index: adult males (38–123%) and females (1–7%).

define the clusters (Smith et al., 2006). We used the JHU White-Matter Tractography Atlas for the MNI 152 brain to define regions with differences in microstructure.

Mean FA values for each individual participant were obtained for the regression and ANOVA analyses from those skeletal voxels that were significantly different before and during treatment.

2.5. Statistical analyses with SPSS

Statistical analyses were performed using SPSS version 16.0 (SPSS Inc., Chicago, Illinois). Within subject ANOVA analyses, with two levels (before and during testosterone treatment), were run for FA and hormonal values. Hierarchical regression analyses were used to identify the predictive value of hormonal variables on FA changes before and during testosterone treatment. The level of significance for all these analyses was set at $p < .05$.

3. Results

3.1. Sample description

The age, education, months of treatment and hormonal levels of the subjects are shown in Table 1.

3.2. FA values before and during cross-sex hormonal treatment

After at least seven months of cross-gender hormonal treatment, TBSS whole brain analyses identified clusters with significant differences between their, before and during testosterone treatment values, in the right SLF and the right CST (see Fig. 1 and Table 2). These results are statistically significant at corrected FWE < 0.05 .

The within subject ANOVA performed on the FA values extracted from the significant regions confirmed the

statistically significant increase in FA values after treatment (Table 3).

3.3. Relationship between FA values in the right SLF and the right CST and hormonal parameters (serum testosterone, SHBG levels and free testosterone index)

We conducted hierarchical regression analyses in which we used serum testosterone, SHBG levels, and the free testosterone index during the hormonal treatment as predictors of the increments of FA values in the SLF and the CST bundles, while controlling for hormonal parameters before the hormonal treatment in the first step of the regression. We did not find any significant relation between the current hormonal levels and the increments in the FA values (all $ps > .46$). As shown in Table 4, the results indicated that the free testosterone index before cross-sex hormonal treatment predicted the increases in the FA values ($ps < .05$). This means that the higher the testosterone index before hormonal treatment, the higher the increases in FA values in the SLF and the CST during androgenization.

4. Discussion

This is the first study to date on the effects of androgenization on the white matter microstructure in FtMs. After at least seven months of treatment, FtMs showed an increment in the FA values of the right SLF and CST. Interestingly enough, these increases were obtained for the same fasciculus in which FtMs before treatment had differed from control females (Rametti et al., 2011a). The observed FA value increases could be predicted by the subjects' pre-hormonal treatment free testosterone index. The higher the free testosterone index before hormonal treatment the higher the increases in FA values seen in the SLF and the CST during testosterone treatment.

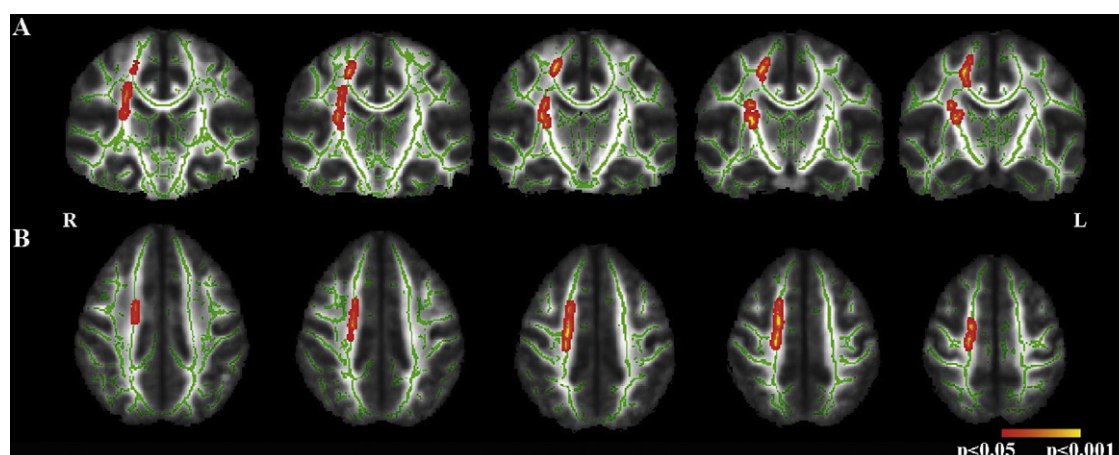


Figure 1 Coronal sections of the corticospinal tract (CST) and axial sections of the superior longitudinal fasciculus (SLF) maps show the locations of the increases of fractional anisotropy (FA) after treatment in androgenized female-to-male transsexuals (FtMs). The group skeleton used for the analysis study is mapped in green. The red color shows clusters of significant FA increases in androgenized FtMs compared to pre treatment values. The threshold for significance was set at $p < .05$. FWE corrected for multiple comparisons. CST: (y: 103, 106, 109, 112, 115); SLF: (z: 113, 116, 119, 122, 125). R: right; L: left.

Table 2 Coordinates of the clusters showing significant differences before and during testosterone treatment in female-to-male transsexuals (FtMs).

Locations	MNI coordinates					Cluster size
	x	y	z	t	p	
FtMs androgenized > FtMs pre-androgenized						
Corticospinal tract (right)	26	-18	11	8.8	<.02	375
Superior Longitudinal Fasciculus (right)	19	-3	49	5.8	<.02	322

Location x, y and z coordinates are based on the atlas of the Montreal Neurological Institute (MNI).

Table 3 Changes in fractional anisotropy values before and during testosterone treatment in female-to male-transsexuals.

	FtMs ^a (pre-androgenized)		FtMs ^a (androgenized)		t	p
	Mean	SD	Mean	SD		
	Corticospinal tract (right)	0.59	0.02	0.62		
Superior longitudinal fasciculus (right)	0.58	0.03	0.63	0.03	7.19	<.001

^a FtMs: female to male transsexuals.

Although there are no previous studies on the effect of testosterone treatment on white matter microstructure, increases in FA values have been reported after pharmacological treatment of geriatric depression (Alexopoulos et al., 2008) and obsessive-compulsive disorder (Yoo et al., 2007). FA changes have also been seen after treatment of dyslexia (Keller and Just, 2009) and after training in games, in white matter areas related to attention control, working memory and problem solving (Lee et al., 2010). Thus, DTI is a suitable technique to identify treatment effects. In the present study testosterone increased the FA values in two brain fasciculi of FtMs: the SLF and the CST.

The SLF is the major cortical association fiber pathway linking anterior prefrontal and posterior parietal associative tertiary areas in both humans and monkeys (Makris et al., 2005; Schmahmann et al., 2007). This fasciculus develops gradually until the late twenties (Lebel et al., 2008), presents sexual dimorphism (Rametti et al., 2011a) and has FA values that exhibit age-related decline consistent with a decrease in white matter integrity (Madden et al., 2009). The SLF integrates inputs from multiple modalities and

belongs to the network for spatial awareness that plays a major role in spatial attention and spatial working memory (Schmahmann and Pandya, 2006) functions which are sexually dimorphic.

In a previous work (Rametti et al., 2011a), in which we studied the same FtMs subjects from the present study before cross-sex hormone treatment and male and female controls, we found that the right SLF of males shows greater FA values than female controls. However, untreated FtMs, like control males, also show greater FA values than control females in the right SLF and the FtMs' values do not differ from male controls'. These results suggested that in FtMs the right SLF is masculinized before the cross-sex hormonal treatment began. In the present study, the same group of FtMs (Rametti et al., 2011a), after testosterone administration, show an increase in the FA values in the SLF.

The CST also showed an increase in FA values after androgenization. The CST is a descending motor pathway originating in the motor cortices and cingulate motor area as well as the primary somatosensory cortex, posterior parietal cortex and the parietal operculum (Lemon, 2008). These motor

Table 4 Summary of hierarchical regression analysis for variables predicting increases of FA values in the superior longitudinal fasciculus and the corticospinal tract ($N = 15$).

Variable	SLF ^a			CST ^b		
	B	SE B	β	B	SE B	β
Step 1						
Testosterone index during androgenization	.022	.016	.361	.019	.014	.342
Step 2						
Testosterone index during androgenization	-.009	.016	-.145	-.007	.015	-.134
Testosterone index before androgenization	.989	.330	.793*	.828	.310	.746*

The measures of the levels of testosterone index previous to the hormonal treatment and testosterone index under treatment were standardized before entered into the regression, * $p < .05$. SLF: step 1: $R^2 = .130$ ($p = .19$, ns), adjusted $R^2 = .063$; step 2: $\Delta R^2 = .373$ ($p = .011$), adjusted $R^2 = .420$. CST: step 1: $R^2 = .1117$ ($p = .21$, ns), adjusted $R^2 = .049$; step 2: $\Delta R^2 = .330$ ($p = .02$), adjusted $R^2 = .354$.

^a Superior longitudinal fasciculus.

^b Corticospinal tract.

fibers control limb movements that require a high degree of skill and flexibility and their lesions affect fine sensorimotor function of the hand (Lemon and Griffith, 2005). The maturation of the corticospinal tract depends on motor experience and genetic factors (Martin et al., 2007; Cheeran et al., 2009). Hervé et al. (2009) found that the CST increased with age in males but not in females in a set of 409 healthy adolescents. Means for the two groups were not different between males and females at 12 years of age, whereas at 18 years of age they were very different. Bio-available testosterone shows a significant increase with age during adolescence only in males. The results of this study suggest that the age-dependent changes observed in males during adolescence are mediated by an effect of testosterone. The authors speculate that testosterone affects the axonal cytoskeleton and, in turn, axonal caliber. Using DTI we have shown that the CST is sexually dimorphic by comparing adult males and females (Rametti et al., 2011a). Furthermore, before the hormonal treatment begins, the FA values of the CST in FtMs fall halfway between those of male and female controls, indicating an incomplete feminization or defeminization (Rametti et al., 2011a).

FA values measure ordered arrangements of myelinated fibers (Beaulieu, 2002) and white matter coherence and axonal organization (Lebel et al., 2008); changes in the microstructure of axons affect FA values. Microtubules, which are composed of tubulin proteins, are the primary cytoskeletal structures in axons and facilitate fast axonal transport. It is known that testosterone up-regulates tubulins and regulates tubulin genes (Fargo et al., 2008). It could be speculated that these anatomofunctional relationships between androgens and the white matter might be involved in the increases of FA values observed in the SLF and the CST of the androgenized FtMs.

The AR gene presents a functional polymorphism determined by the number of CAG repeats in exon 1 of the gene. The number of CAG repeats is inversely related to the transcriptional activity of androgen-dependent genes (Hsiao et al., 1999). No significant differences were reported in the number of CAG repeats between FtMs and control females (Ujike et al., 2009). However, Paus et al. (2010) studied normal adolescents and classified them with respect to the number of CAG repeats in "short" (≥ 22 CAG repeats) and "long" (≥ 23 CAG repeats) AR. They also measured testosterone levels. These authors found that in male adolescents the functional polymorphism of AR moderated the effect of testosterone on the relative white and gray matters volumes, and the higher the bioavailable testosterone levels, the higher the absolute and relative white matter volume. It seems that in our study the FA of FtMs behaves in a similar way. In androgenized FtMs a high free testosterone index before treatment predicts a large increase in FA values; this might signal differences in AR sensitivity within this group, with a stronger response to androgen treatment being observed in those individuals with a short CAG repeat.

The effect of testosterone treatment on the SLF and the CST also has consequences for understanding brain sex differences in our species. The development of brain sex differences is a multisignaling process (Segovia et al., 1999) produced either due to gonadal hormones or to sex-specific gene expression (McCarthy and Arnold, 2011). It is important to note that androgenized FtMs show increases in FA values

only in fascicles that show sex differences and are already masculinized (SLF) or defeminized (CST) before testosterone treatment (Rametti et al., 2011a). FtMs are biologically and endocrinologically female. However, their SLF is masculinized and their CST is defeminized and both respond to testosterone in a manner that is predicted by the high free testosterone index before treatment. This suggests that FtMs' SLF and CST have ARs located either in the soma or in the axons of the cells. Moreover, pretreatment, the SLF is already organized in a masculine manner and the CST is defeminized in FtMs; the testosterone treatment enhances the FA values in both fascicles, but this enhancement depends on the pretreatment testosterone bioavailability. This differential degree of response to testosterone might be signalling different degrees of masculinization (SLF) or defeminization (CST).

FtMs before testosterone treatment present a female phenotype with a masculine and/or defeminized profile in brain bundles that are related to complex cognitive function. Only these bundles respond to androgenization and they do so in the way that males respond. However, other body tissues are also masculinized by testosterone treatment (Mueller et al., 2007; Gooren and Giltay, 2008; Meriggiola et al., 2008). With respect to the brain, it seems that androgenization is more selective, acting only on those aspects that are already organized in a masculine manner or are already defeminized.

The present study has some limitations. Androgen therapy in transsexuals also affects several other hormones such as cortisol and estrogens and this has not been analyzed in the current study. Moreover, the chronic administration of androgens could have affected the FA values early during the treatment and we would have missed the exact time point of that effect because of our study design. Nonetheless, a follow up study doing MRI scanning early during treatment and later could help, but it is difficult to justify repetitive scans.

In conclusion, during testosterone treatment FtMs showed increases of FA values in brain bundles that were already masculinized or defeminized before androgen treatment. Thus, testosterone acts on the white matter microstructure ordering its coherence and axonal organization. Moreover, the size of this effect depends on the bio-availability of testosterone before beginning the hormone treatment.

Role of funding source

Funding for this study was provided by the Spanish Ministerio de Ciencia e Innovación (MNICIN), Grant SEJ2011-24496. The MNICIN had no further role in any step of the present study.

Conflict of interest

None.

Contributors

Conception and design: Beatriz Carrillo, Esther Gómez-Gil, Carme Junque, Santiago Segovia, Giuseppina Rametti and Antonio Guillamon.

Acquisition of data: Beatriz Carrillo, Leire Zubiaurre-Elorza and Giuseppina Rametti.

Analysis and interpretation of data: Beatriz Carrillo, Esther Gómez-Gil, Carme Junque, Angel Gomez and Antonio Guillamon.

Drafting the article: Beatriz Carrillo, Esther Gómez-Gil, Carme Junque and Antonio Guillamon.

Revising it for intellectual content: Beatriz Carrillo, Esther Gómez-Gil, Giuseppina Rametti, Carme Junque, Angel Gomez, Kazmer Karadi, Santiago Segovia and Antonio Guillamon.

Final approval of the completed article: Beatriz Carrillo, Esther Gómez-Gil, Giuseppina Rametti, Carme Junque, Angel Gomez, Kazmer Karadi, Santiago Segovia and Antonio Guillamon.

Acknowledgments

We are grateful to the patients that voluntarily participate in the study. Thanks to Drs. N. Bargalló, C. Falcón, J. Llul, J.M. Reales and S. Juanes for their help at some phases of the study and to R. Sánchez and C.F. Warren for their editorial help.

References

- Abdelgadir, S.E., Roselli, C.E., Choate, J.V.A., Resko, J.A., 1999. Androgen receptor messenger ribonucleic acid in brains and pituitaries of male rhesus monkeys: studies on distribution, hormonal control, and relationship to luteinizing hormone secretion. *Biol. Reprod.* 60, 1251–1256.
- Alexopoulos, G.S., Murphy, C.F., Gunning-Dixon, F.M., Latoussakis, V., Kanelopoulos, D., Klimstra, S., Lim, K.O., Hoptman, M.J., 2008. Microstructural white matter abnormalities and remission of geriatric depression. *Am. J. Psychiatry* 165, 238–244.
- American Psychiatric Association, 2000. *Diagnostic and Statistical Manual of Mental Disorders*, 4th ed. DSM-IV-TR, Washington, DC.
- Andersson, J.L.R., Jenkinson, M., Smith, S., 2007a. Non-linear optimisation. FMRIB technical report TR07JA1 from www.fmrib.ox.ac.uk/analysis/techrep
- Andersson, J.L.R., Jenkinson, M., Smith, S., 2007b. Non-linear registration, aka Spatial normalization. FMRIB technical report TR07JA2 from www.fmrib.ox.ac.uk/analysis/techrep.
- Beaulieu, C., 2002. The basis of anisotropic water diffusion in the nervous system – a technical review. *NMR Biomed.* 15, 435–455.
- Berglund, H., Lindstrom, P., Dhejne-Helmy, C., Savic, I., 2008. Male-to-female transsexuals show sex-atypical hypothalamus activation when smelling odorous steroids. *Cereb. Cortex* 18, 1900–1908.
- Beyenburg, S., Watzka, M., Clusmann, H., Blümcke, I., Bidlingmaier, F., Elger, C.E., Stoffel-Wagener, B., 2000. Androgen receptor mRNA expression in the human hippocampus. *Neurosci. Lett.* 294, 25–28.
- Bezdicikova, M., Molikova, R., Bebarova, L., Kolar, Z., 2007. Distribution of nuclear receptors for steroid hormones in the human brain: a preliminary study. *Biomed. Pap. Med. Fac. Univ. Palacky Olomouc Czech. Repub.* 151, 69–71.
- Carrillo, B., Gómez-Gil, E., Rametti, G., Junque, C., Gomez, A., Karadi, K., Segovia, S., Guillamon, A., 2010. Cortical activation during mental rotation in male-to-female and female-to-male transsexuals under hormonal treatment. *Psychoneuroendocrinology* 35, 1213–1222.
- Cheeran, B.J., Ritter, C., Rothwell, J.C., Siebner, H.R., 2009. Mapping genetic influences on the corticospinal motor system in humans. *Neuroscience* 164, 156–163.
- Cohen-Kettenis, P.T., Gooren, L.J., 1999. Transsexualism: a review of etiology, diagnosis and treatment. *J. Psychosom. Res.* 46, 315–333.
- DonCarlos, L.L., Garcia-Ovejero, D., Sarkey, S., Garcia-Segura, L.M., Azcoitia, I., 2003. Androgen receptor immunoreactivity in forebrain axons and dendrites in the rat. *Endocrinology* 144, 3632–3638.
- DonCarlos, L.L., Sarkey, S., Lorenz, B., Azcoitia, I., Garcia-Ovejero, D., Huppenbauer, C., Garcia-Segura, L.M., 2006. Novel cellular phenotypes and subcellular sites for androgen action in the forebrain. *Neuroscience* 138, 801–807.
- Emory, L.E., Williams, D.H., Cole, C.M., Amparo, E.G., Meyer, W.J., 1991. Anatomic variation of the corpus callosum in persons with gender Dysphoria. *Arch. Sex. Behav.* 20, 409–417.
- Fargo, K.N., Galbiati, M., Foecking, E.M., Poletti, A., Jones, K.J., 2008. Androgen regulation of axon growth and neurite extension in motoneurons. *Horm. Behav.* 53, 716–728.
- Fernández-Guasti, A., Kruijver, F.P., Fodor, M., Swaab, D.F., 2000. Sex differences in the distribution of androgen receptors in the human hypothalamus. *J. Comp. Neurol.* 425, 422–435.
- Finley, S.K., Kritzer, M.F., 1999. Immunoreactivity for intracellular androgen receptors in identified subpopulations of neurons astrocytes and oligodendrocytes in primate prefrontal cortex. *J. Neurobiol.* 40, 446–457.
- Garcia-Falgueras, A., Swaab, D.F., 2008. A sex difference in the hypothalamic uncinate nucleus: relationship to gender identity. *Brain* 131, 3132–3146.
- Gizewski, E.R., Krause, E., Schlamann, M., Happich, F., Ladd, M.E., Forsting, M., Senf, W., 2009. Specific cerebral activation due to visual erotic stimuli in male-to-female transsexuals compared with male and female controls: an fMRI study. *J. Sex. Med.* 6, 440–448.
- Gómez-Gil, E., Trilla, A., Salamero, M., Godas, T., Valdes, M., 2009. Sociodemographic, clinical, and psychiatric characteristics of transsexuals from Spain. *Arch. Sex. Behav.* 38, 378–392.
- Gooren, L.J., Giltay, E.J., 2008. Review of studies of androgen treatment of female-to-male transsexuals: effects and risks of administration of androgens to females. *J. Sex. Med.* 5, 765–776.
- Hervé, P.Y., Leonard, G., Perron, M., Pike, B., Pitiot, A., Richer, L., Veillette, S., Pausova, Z., Paus, T., 2009. Handedness, motor skills and maturation of the corticospinal tract in the adolescent brain. *Hum. Brain Mapp.* 30, 3151–3162.
- Hsiao, P.W., Lin, D.L., Nakao, R., Chang, C., 1999. The linkage of Kennedy's neuron disease to ARA24, the first identified androgen receptor polyglutamine region-associated coactivator. *J. Biol. Chem.* 274, 20229–20234.
- Hulshoff Pol, H.E., Cohen-Kettenis, P.T., Van Haren, N.E.M., Peper, J.S., Brans, R.G.H., Cahn, W., Schnack, H.G., Gooren, L.J.G., Kahn, R.S., 2006. Changing your sex changes your brain: influences of testosterone and estrogen on adult human brain structure. *Eur. J. Endocrinol.* 155, s107–s114.
- Huster, R.J., Westerhausen, R., Kreuder, F., Schweiger, E., Wittling, W., 2009. Hemispheric and gender related differences in the midcingulum bundle: a DTI study. *Hum. Brain Mapp.* 30, 383–391.
- Keller, T.A., Just, M.A., 2009. Altering cortical connectivity: remediation-induced changes in the white matter of poor readers. *Neuron* 64, 624–631.
- Kruijver, F.P., Zhou, J.N., Pool, C.W., Hofman, M.A., Gooren, L.J., Swaab, D.F., 2000. Male-to-female transsexuals have female neuron numbers in a limbic nucleus. *J. Clin. Endocrinol. Metab.* 85, 2034–2041.
- Kruijver, F.P., Balesar, R., Espila, A.M., Unmehopa, U.A., Swaab, D.F., 2002. Estrogen receptor-alpha distribution in the human hypothalamus in relation to sex and endocrine status. *J. Comp. Neurol.* 9, 115–139.

- Kruijver, F.P., Balesar, R., Espila, A.M., Unmehopa, U.A., Swaab, D.F., 2003. Estrogen-receptor-beta distribution in the human hypothalamus: similarities and differences with ER alpha distribution. *J. Comp. Neurol.* 10, 251–277.
- Lebel, C., Walker, L., Leemans, A., Phillips, L., Beaulieu, C., 2008. Microstructural maturation of the human brain from childhood to adulthood. *Neuroimage* 40, 1044–1055.
- Lee, B., Park, J.-Y., Jung, W.H., Kim, H.S., Jungsu, S., Choi, C.-H., Jang, J.H., Kang, D.H., Kwon, J.S., 2010. White matter neuroplastic changes in long-term trained players of the game of "Baduk" (GO): a voxel-based diffusion-tensor imaging study. *Neuroimage* 52, 9–19.
- Lemon, R.N., 2008. Descending pathways in motor control. *Annu. Rev. Neurosci.* 31, 195–218.
- Lemon, R.N., Griffith, J., 2005. Comparing the function of the corticospinal system in different species: organizational differences for motor specialization. *Muscle Nerve* 32, 261–279.
- Luders, E., Sanchez, F.J., Gaser, C., Toga, A.W., Narr, K.L., Hamilton, L.S., Vilain, E., 2009. Regional gray matter variation in male-to-female transsexualism. *Neuroimage* 46, 904–907.
- Madden, D.J., Spaniol, J., Costello, M.C., Bucur, B., White, L.E., Cabeza, R., Davis, S.W., Dennis, N.A., Provenzale, J.M., Huettel, S.A., 2009. Cerebral white matter integrity mediates adult age differences in cognitive performance. *J. Cogn. Neurosci.* 21, 289–302.
- Makris, N., Kennedy, D.N., McInerney, S., Sorensen, A.G., Wang, R., Caviness, V.S., Pandya, D.N., 2005. Segmentation of subcomponents within the superior longitudinal fasciculus in humans: a quantitative, in vivo, DT-MRI study. *Cereb. Cortex* 15, 854–869.
- Martin, J., Friel, K., Salimi, I., Chakrabarty, S., 2007. Activity- and use-dependent plasticity of the developing corticospinal system. *Neurosci. Biobehav. Rev.* 31, 1125–1135.
- McCarthy, M.M., Arnold, A.P., 2011. Reframing sexual differentiation of the brain. *Nat. Neurosci.* 14, 677–683.
- Merigliola, M.C., Armillotta, F., Costantino, A., Altieri, P., Saad, F., Kalhorn, T., Perrone, A.M., Ghi, T., Pelusi, G., 2008. Effects of testosterone undecanoate administered alone or in combination with letrozole or dutasteride in female to male transsexuals. *J. Sex. Med.* 5, 2442–2453.
- Meyer, W.J., Bockting, W.O., Cohen-Kettenis, P., Coleman, E., DiCeglie, D., Devore, H., Gooren, L., Hage, J.J., Kirk, S., Kuiper, B., Laub, D., Lawrence, A., Menard, Y., Patton, J., Shaefer, L., Webb, A., Christine, C., Monstrey, S., 2002. The standards of care for gender identity disorders, 6th version. *J. Psychol. Hum. Sex.* 13, 1–30.
- Miller, K.K., Rosner, W., Lee, H., Hier, J., Sesmilo, G., Schoenfeld, D., Neubauer, G., Klibanski, A., 2004. Measurement of free testosterone in normal women and women with androgen deficiency: comparison of methods. *J. Clin. Endocrinol. Metab.* 89, 525–533.
- Mueller, A., Kiesewetter, F., Binder, H., Beckmann, M.W., Dittrich, R., 2007. Long-term administration of testosterone undecanoate every 3 months for testosterone supplementation in female-to-male transsexuals. *J. Clin. Endocrinol. Metab.* 92, 3470–3475.
- Nucifora, P.G., Verma, R., Lee, S.-K., Melhem, E.R., 2007. Diffusion-tensor MR imaging and tractography: exploring brain microstructure and connectivity. *Radiology* 245, 367–384.
- Österlund, M.K., Keller, E., Hurd, Y.L., 2000a. The human forebrain has discrete estrogen receptor α messenger RNA expression: high levels in the amygdaloid complex. *Neuroscience* 95, 333–342.
- Österlund, M.K., Gustafsson, J.-A., Keller, E., Hurd, Y.L., 2000b. Estrogen receptor β (ER β) messenger ribonucleic acid (mRNA) expression within the human forebrain: distinct distribution pattern to ER α mRNA. *J. Clin. Endocrinol. Metab.* 85, 3840–3846.
- Paus, T., Nawaz-Khan, I., Leonard, G., Perron, M., Pike, G.B., Pitiot, A., Richer, L., Susman, E., Veillette, S., Pausova, Z., 2010. Sexual dimorphism in the adolescent brain: role of testosterone and androgen receptor in global and local volumes of grey and white matter. *Horm. Behav.* 57, 63–75.
- Perrin, J.S., Hervé, P.Y., Leonard, G., Perron, M., Pike, G.B., Pitiot, A., Richer, L., Veillette, S., Pausova, Z., Paus, T., 2008. Growth of white matter in the adolescent brain: role of testosterone and androgen receptor. *J. Neurosci.* 28, 9519–9524.
- Puy, L., MacLusky, N.J., Becker, L., Karsan, N., Trachtenberg, J., Brown, T.J., 1995. Immunocytochemical detection of androgen receptor in human temporal cortex: characterization and application of polyclonal androgen receptor antibodies in frozen and paraffin-embedded tissues. *J. Steroid Biochem. Mol. Biol.* 55, 197–209.
- Rametti, G., Carrillo, B., Gómez-Gil, E., Junque, C., Segovia, S., Gomez, A., Guillamon, A., 2011a. White matter microstructure in female to male transsexuals before cross-sex hormonal treatment. A diffusion tensor imaging study. *J. Psychiatr. Res.* 45, 199–204.
- Rametti, G., Carrillo, B., Gómez-Gil, E., Junque, C., Zubiarré-Elorza, L., Segovia, S., Gomez, A., Guillamon, A., 2011b. The microstructure of white matter in male to female transsexuals before cross-sex hormonal treatment. A DTI study. *J. Psychiatr. Res.* 45, 949–954.
- Sarkey, S., Azcoitia, I., Garcia-Segura, L.M., Garcia-Ovejero, D., DonCarlos, L.L., 2008. Classical androgen receptors in non-classical sites in the brain. *Horm. Behav.* 53, 753–764.
- Savic, I., Garcia-Falgueras, A., Swaab, D., 2010. Sexual differentiation of the human brain in relation to gender identity and sexual orientation. *Prog. Brain Res.* 186, 41–62.
- Savic, I., Arver, S., 2011. Sex dimorphism of the brain in male-to-female transsexuals. *Cereb. Cortex* 21, 2525–2533.
- Schmahmann, J.D., Pandya, D.N., 2006. *Fiber Pathways of the Brain*. Oxford University Press, Oxford.
- Schmahmann, J.D., Pandya, D.N., Wang, R., Dai, G., D'Arceuil, H.E., de Crespigny, A.J., Wedeen, V.J., 2007. Association fibre pathways of the brain: parallel observations from diffusion spectrum imaging and autoradiography. *Brain* 130, 630–653.
- Schmithorst, V.J., Holland, S.K., Dardzinski, B.J., 2008. Developmental differences in white matter architecture between boys and girls. *Hum. Brain Mapp.* 29, 696–710.
- Schöning, S., Engeli, A., Bauer, C., Kugel, H., Kersting, A., Roestel, C., Zwitterlood, P., Pyka, M., Dannlowski, U., Lehmann, W., Heindel, W., Arolt, V., Konrad, C., 2010. Neuroimaging differences in spatial cognition between men and male-to-female transsexuals before and during hormone therapy. *J. Sex. Med.* 5, 1858–1867.
- Segovia, S., Guillamon, A., del Cerro, M.C., Ortega, E., Pérez-Laso, C., Rodriguez-Zafra, M., Beyer, C., 1999. The development of brain sex differences: a multisignaling process. *Behav. Brain Res.* 105, 69–80.
- Smith, S.M., 2002. Fast robust automated brain extraction. *Hum. Brain Mapp.* 17, 143–155.
- Smith, S.M., Jenkinson, M., Woolrich, M.W., Beckmann, C.F., Behrens, T.E.J., Johansen-Berg, H., Bannister, P.R., De Luca, M., Drobnjak, I., Flitney, D.E., Niazy, R.K., Saunders, J., Vickers, J., Zhang, Y., De Stefano, N., Brady, J.M., Matthews, P.M., 2004. Advances in functional and structural MR image analysis and implementation as FSL. *Neuroimage* 23, S208–S219.
- Smith, S.M., Jenkinson, M., Johansen-Berg, H., Rueckert, D., Nichols, T.E., Mackay, C.E., Watkins, K.E., Ciccarelli, O., Cader, M.Z., Matthews, P.M., Behrens, T.E., 2006. Tract-based spatial statistics: voxelwise analysis of multi-subject diffusion data. *Neuroimage* 31, 1487–1505.
- Sommer, I.E.C., Cohen-Kettenis, P.T., van Raalten, T., vd Veer, A.J., Ramsey, L.E., Gooren, L.J.G., Kahn, R.S., Ramsey, N.F., 2008. Effects of cross-sex hormones on cerebral activation during language and mental rotation: an fMRI study in transsexuals. *Eur. Neuropsychopharmacol.* 18, 215–221.
- Ujike, H., Otani, K., Nakatsuka, M., Ishii, K., Sasaki, A., Oishi, T., Sato, T., Okahisa, Y., Matsumoto, Y., Namba, Y., Kimata, Y., Kuroda, S., 2009. Association study of gender identity disorder

- and sex hormone-related genes. *Prog. Neuropsychopharmacol. Biol. Psychiatry* 33, 1241–1244.
- Vermeulen, A., Verdonck, L., Kaufman, J.M., 1999. A critical evaluation of simple methods for the estimation of free testosterone in serum. *J. Clin. Endocrinol. Metab.* 10, 3666–3672.
- Westerhausen, R., Walter, C., Kreuder, F., Wittling, R.A., Schweiger, E., Wittling, W., 2003. The influence of handedness and gender on microstructure of the human corpus callosum: a diffusion-tensor magnetic resonance imaging study. *Neurosci. Lett.* 351, 99–102.
- World Health Organization (WHO), 1993. The ICD-10. Classification of mental and behavioural disorders. In: *Diagnostic Criteria for Research*, Geneva.
- Yoo, S.Y., Jang, J.H., Shin, Y.W., Kim, D.J., Park, H.J., Moon, W.J., Chung, E.C., Lee, J.M., Kim, I.Y., Kim, S.I., Kwon, J.S., 2007. White matter abnormalities in drug-naïve patients with obsessive–compulsive disorder: a diffusion tensor study before and after citalopram treatment. *Acta Psychiatr. Scand.* 116, 211–219.
- Yokota, Y., Kawamura, Y., Kameya, Y., 2005. Callosal shapes at the midsagittal plane: MRI differences of normal males, normal females, and GID. *Conf. Proc. IEEE Eng. Med. Biol. Soc.* 3, 3055–3058.
- Zhou, J.N., Hofman, M.A., Gooren, L.J., Swaab, D.F., 1995. A sex difference in the human brain and its relation to transsexuality. *Nature* 378, 68–70.